

PATIENT

Tasha Almeida

SPECIES

Canine

BREED

Mix

SEX

Female Spayed

AGE

11 years

WEIGHT

17.3lbs

PRESENTING CLINICAL SIGNS

History: Progressive heart murmur, now grade IV/VI holosystolic. Worsening dry, retching, cough, non-productive. No tachypnea/dyspnea. Resting RR at home =32. On Dextromorphan 30mg/5ml-1ml PO 1-2x daily for cough. On Denamarin (elevated liver values).

ECHOCARDIOGRAM FINDINGS

2D, m-mode, color flow and Doppler imaging is available.

Left ventricle: LV is mildly dilated with hyperdynamic myocardial function.

Left atrium: The left atrium is severely dilated.

Mitral valve: Diffuse thickening of mitral valve leaflets with mild prolapse into the left atrial lumen. Severe eccentric mitral regurgitation, normal velocity.

Aortic valve/Aorta: The aortic valve is normal in morphology and mobility. Normal aortic outflow velocity; laminar flow. No aortic insufficiency.

Right ventricle: Mild RV enlargement.

Right atrium: Mild RA enlargement.

Tricuspid valve: The tricuspid valve appears mildly thickened with mild tricuspid regurgitation. TR velocity consistent with mild pulmonary hypertension.

Pulmonic valve/Pulmonary artery: The pulmonic valve is normal in morphology and mobility. Normal pulmonic outflow velocities. No pulmonic insufficiency.

Pericardium/other: No pericardial or pleural effusion noted. No obvious cardiac masses

Heart rhythm: ECG reveals a sinus rhythm with an average HR of 90bpm.

2-Dimensional Measurements

Ao diam (cm)	1.5
LA diam (cm)	3.3
LA:Ao (Swe)	2.2
IVS thickness (cm)	0.6
LVID diastole (cm)	3.4
PW thickness (cm)	0.6
LVID systole (cm)	1.6
FS (%)	52

Doppler Measurements

PV Vmax (m/s)	0.54
AoV Vmax (m/s)	1.7
MR Vmax (m/s)	4.8
TR Vmax (m/s)	3.0
TR PG (mmHg)	36

INTERPRETED BY

Maggie Machen
Lamy, DVM
DACVIM (Cardiology)

IMAGING PERFORMED BY

Pamela Harrigan,
RDCS

HOSPITAL NAME

Compassionate Care
Veterinary Clinic

REFERRING VET

Dr. Coates

INVOICE

27289

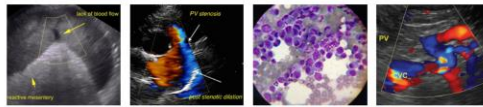
DATE

11/4/22

INTERPRETATION OF THE FINDINGS

The murmur is due to chronic degenerative valve disease causing severe mitral and mild tricuspid regurgitation. Severe left atrial enlargement indicates the risk for spontaneous congestive heart failure is elevated going forward. Early PAH is documented, which is not surprising in a coughing dog with severe LA dilation. No additional issues such as systolic dysfunction are noted.

A cough in this patient with this degree of heart disease is likely multi-factorial in origin, including mainstem bronchi compression and/or potentially some degree of upper or lower airway disease given the breed. Early CHF/pulmonary edema should also be considered; however, this is less likely based upon the history and radiographic evaluation. Recommend institute cardiac supportive medications including a weak diuretic (Spironolactone) and advise close monitoring at home for need for Lasix therapy. Pending response, cough suppression (up to q4-6 hours) may also be helpful for mechanical cough. Monitoring of sleeping breathing rates is recommended as the best way to screen for CHF at home.



PATIENT

Tasha Almeida

Long term prognosis is guarded; however, I am hopeful we can stabilize the patient for some time on medications. Once CHF develops, they are generally able to maintain a good quality of life for an average of 8-12 months. Patient will always be at risk for progression to CHF, development of arrhythmias/LA tear, syncope and/or sudden death in the future.

SPECIES

Canine

RECOMMENDATIONS

BREED

Mix

- Consider CXR.
- Institute ACE-I (benazepril or enalapril) 0.5mg/kg PO q12h.
- Institute Pimobendan 0.3mg/kg PO q12h.
- Institute Spironolactone 1-2mg/kg PO q12h.

SEX

Female Spayed

- Consider hydrocodone with homatropine for QOL (0.2-0.4mg/kg PO up to q4-6 hours PRN for cough; available in 5/1.5mg tabs and 5mg/5ml liquid suspension).
- Consider a course of Baytril depending on severity of the cough.
- Elective anesthesia is not advised.

AGE

11 years

- Omega fatty acid supplementation and mild salt restriction may be of some long-term benefit.
- Monitor for development of a cough, labored breathing, exercise intolerance or collapse episodes. Monitoring of sleeping breathing rates is the best way to screen for progression to CHF at home.

WEIGHT

17.3lbs

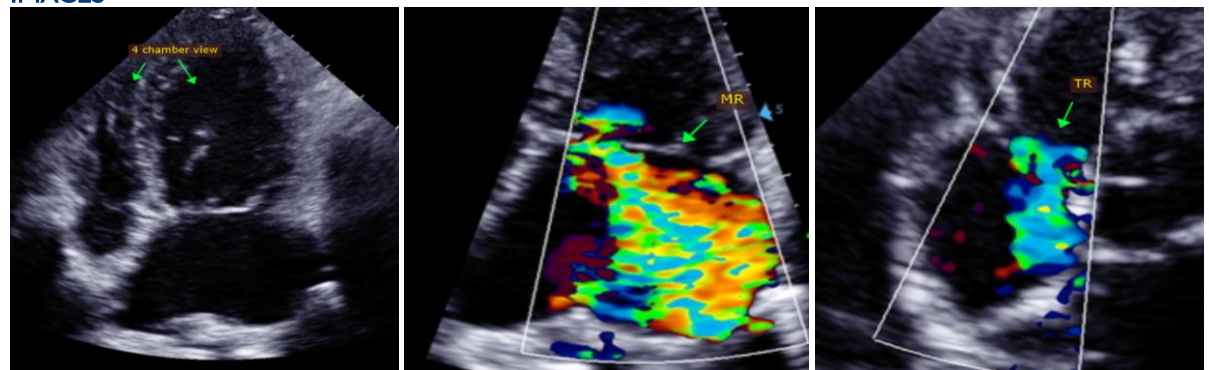
PLAN

- A renal panel is recommended in 1-2 weeks, then every 3-4 months lifelong.
- A recheck echocardiogram is recommended in 4-6 months to screen for progression, sooner if clinical signs arise.

INTERPRETED BY

Maggie Machen
 Lamy, DVM
 DACVIM (Cardiology)

IMAGES



IMAGING PERFORMED BY

Pamela Harrigan,
 RDCS

HOSPITAL NAME

Compassionate Care
 Veterinary Clinic

REFERRING VET

Dr. Coates

The information and recommendations provided are based on the images presented by the referring veterinarian. No evaluation can be communicated regarding pathology that was not visible in the image/video clips provided.

INVOICE

27289

Thank you for this referral. This report was generated using transcription software, and minor dictation errors may be present. If the clinical or image interpretation does not parallel your findings or if I can be of any further assistance, please contact me.

DATE

11/4/22

Maggie Machen Lamy, DVM
 Diplomat of the American College of Veterinary Internal Medicine (Cardiology)
 info@sonopath.com